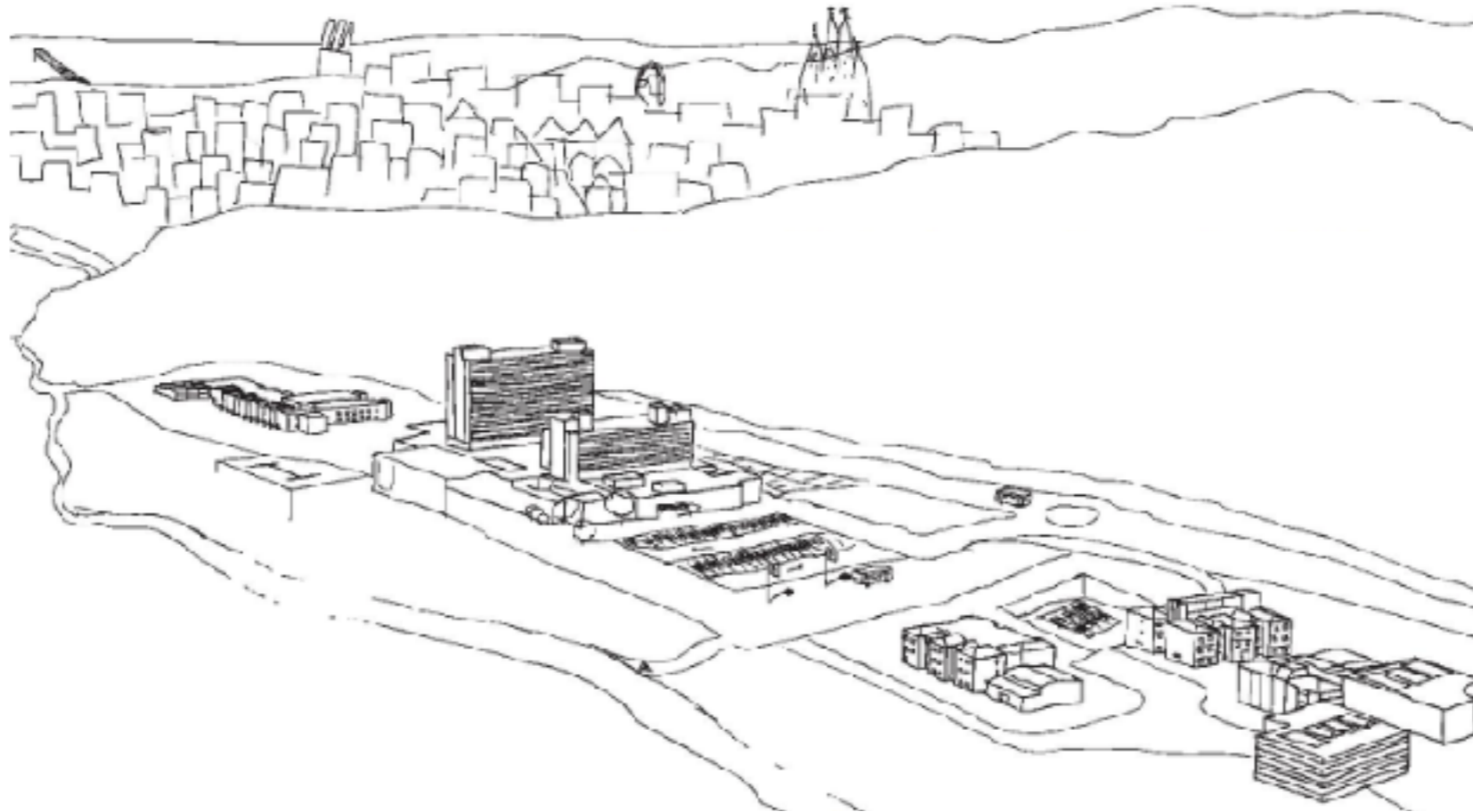

ICP COMPLEJA



Germans Trias i Pujol
Hospital
Institut Català de la Salut

Institut Català de la Salut



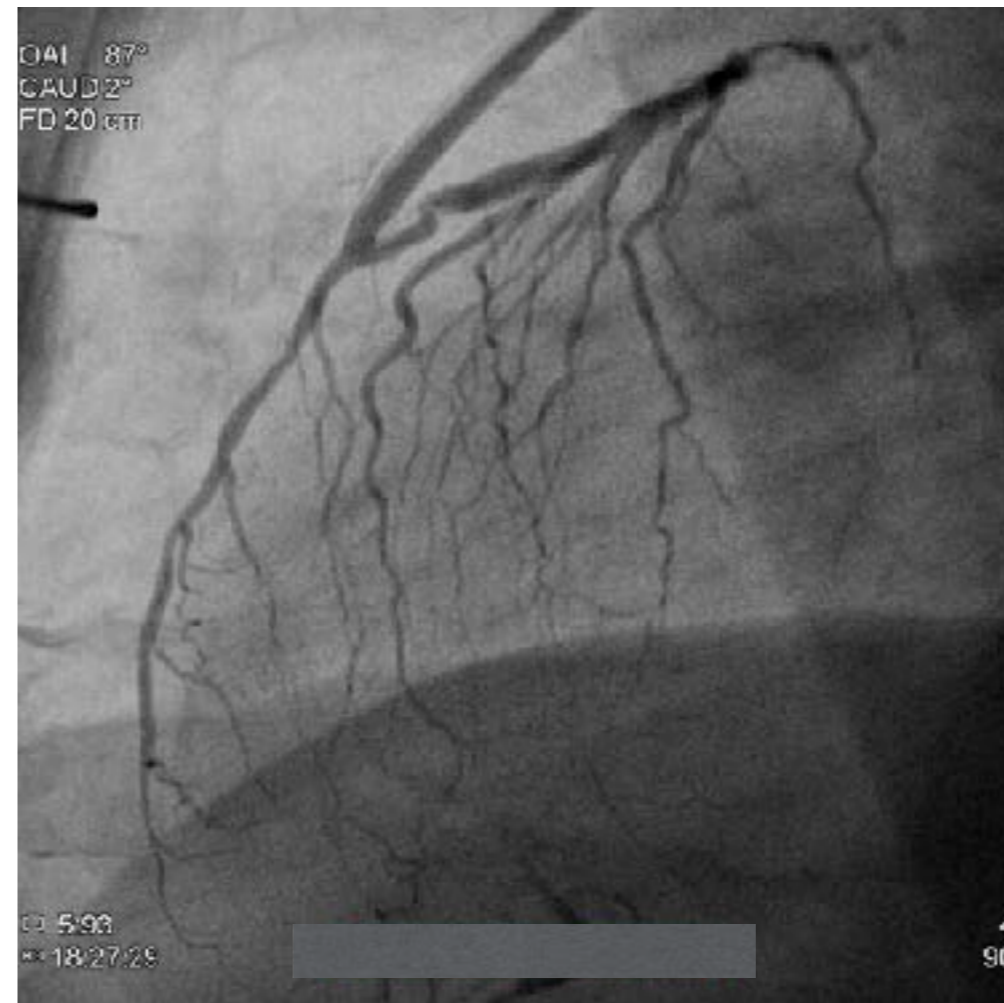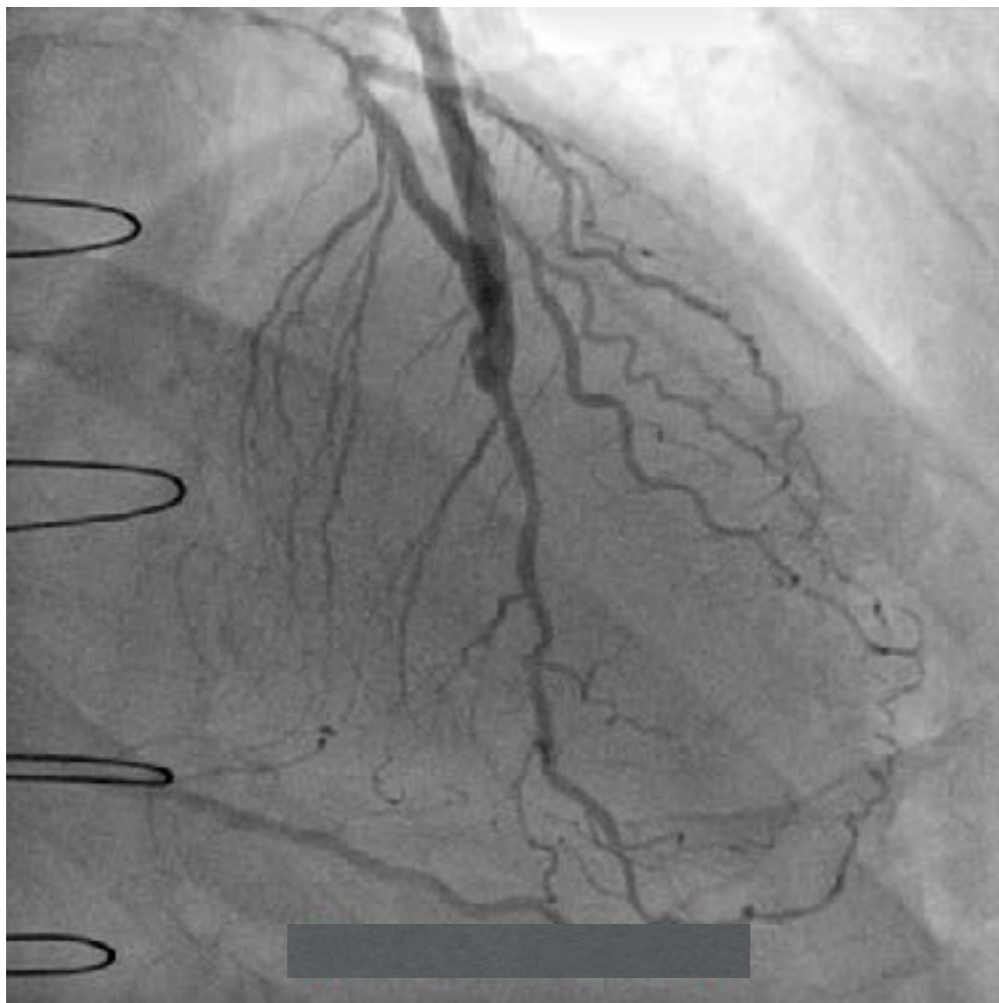
iCor.cat

ICOL'CSIC

- VCP
- Varon 78 años, dislipémico
- 1993 IAM inferior
- 1999 Angina. enfermedad 3 vasos. CABG mamaria a DA i safena a MO
- Ingreso actual por SCASEST
- SPECT Isquemia inferior. FE 50%.

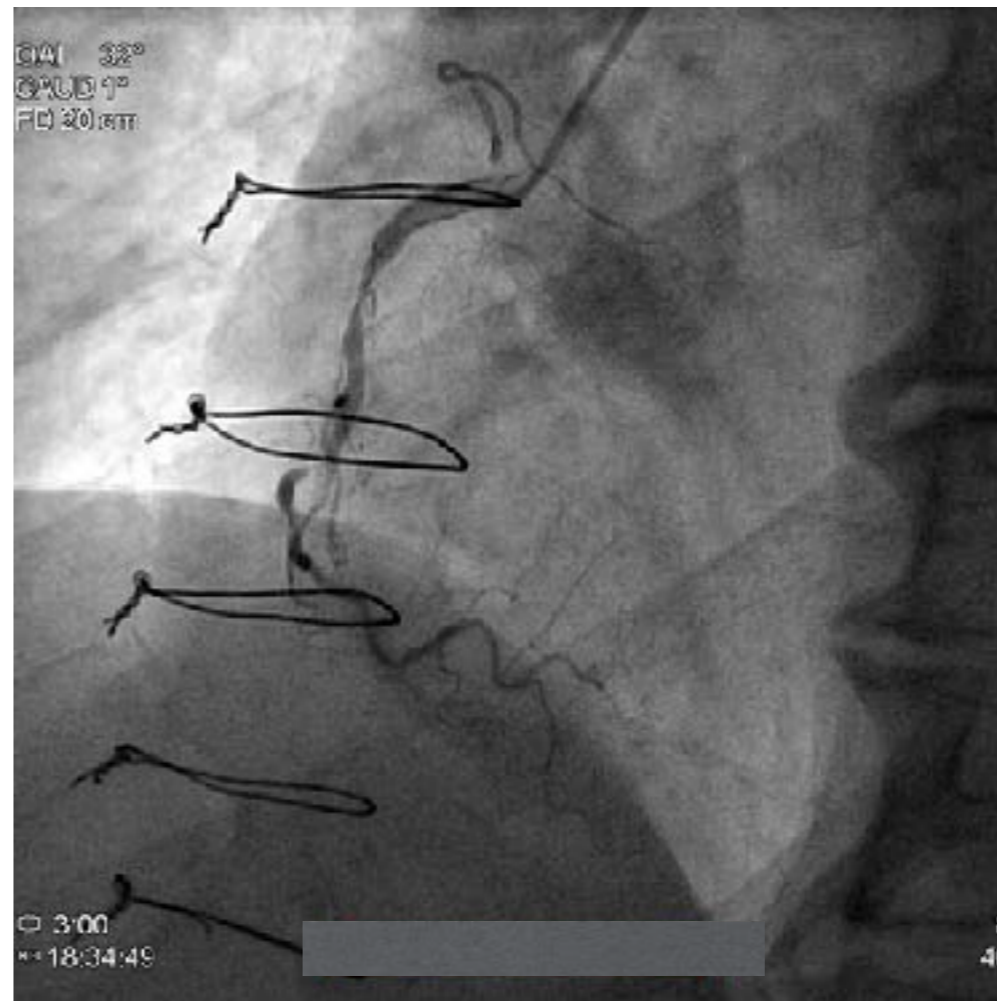
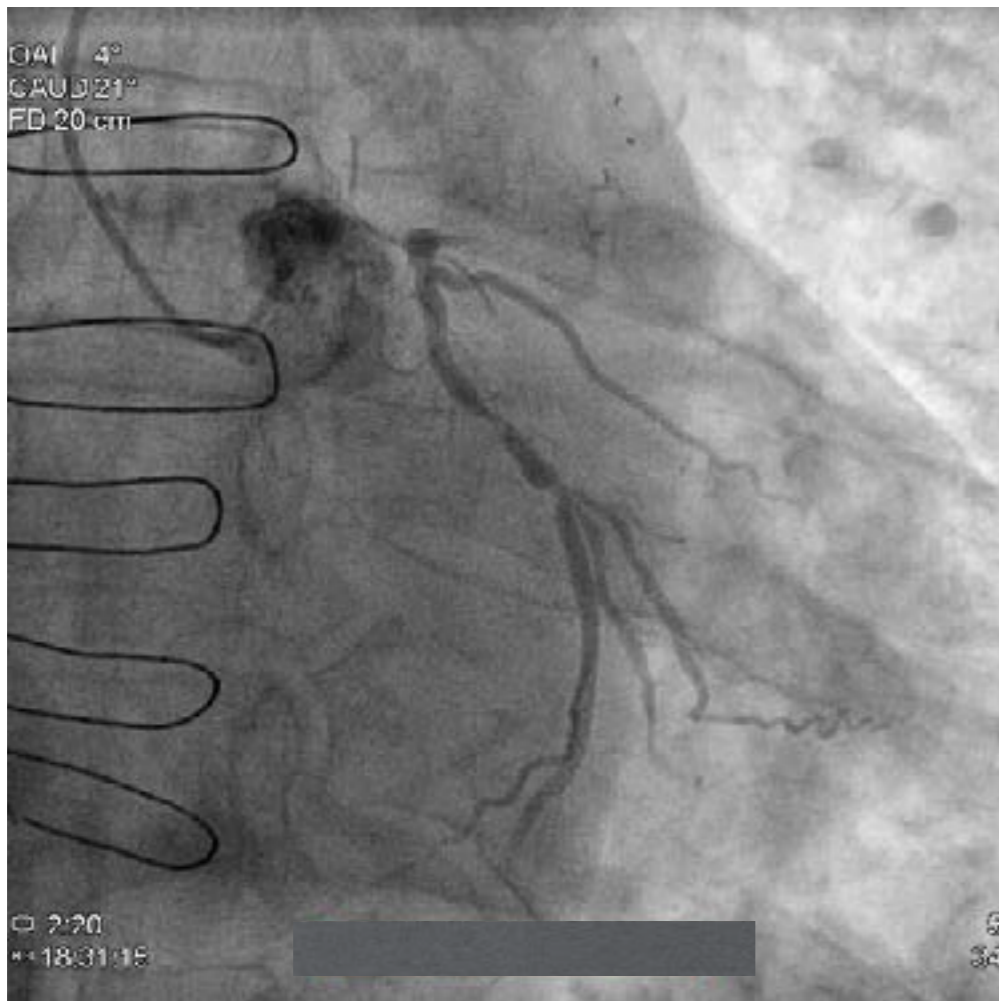Coronariografía

Mamaria a DA permeable, circulación colateral a CD



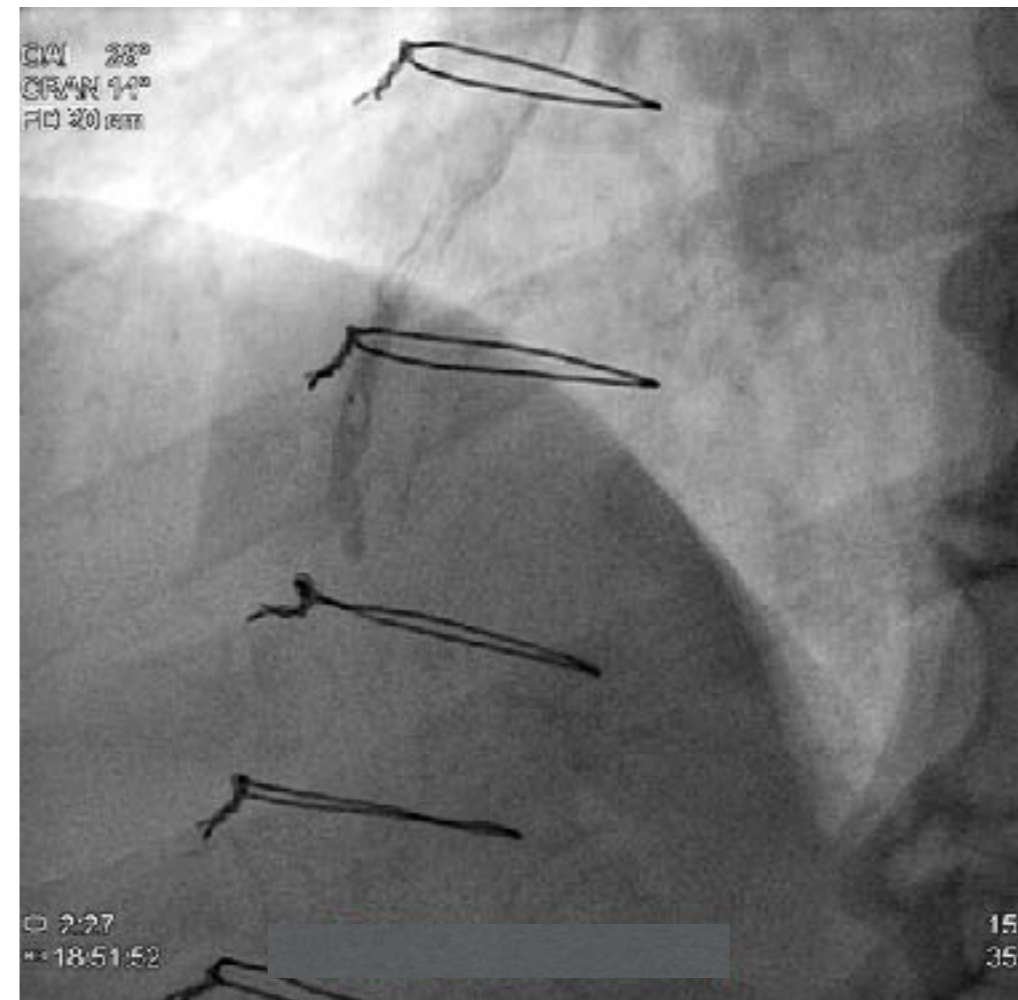
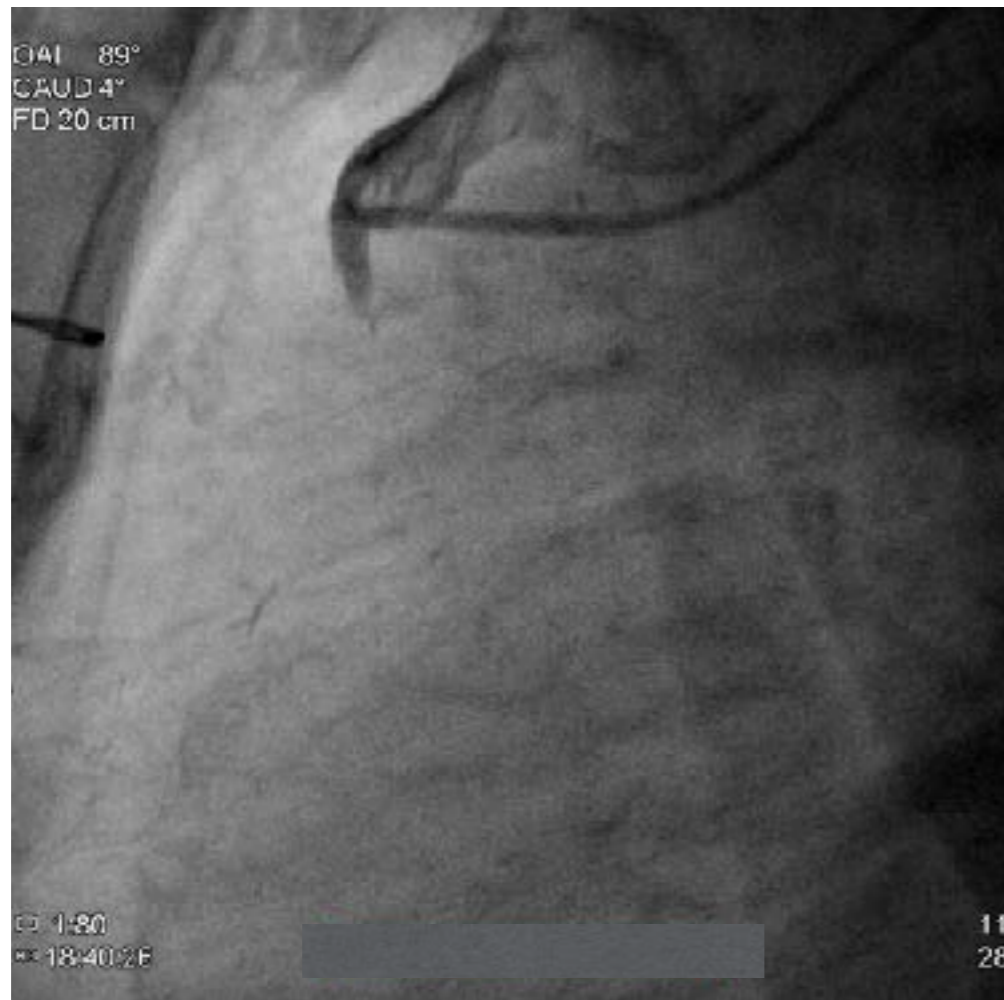
Coronariografía

TC lesion severa, DA ocluida, CF enfermedad difusa, CD severamente calcificada y ocluida

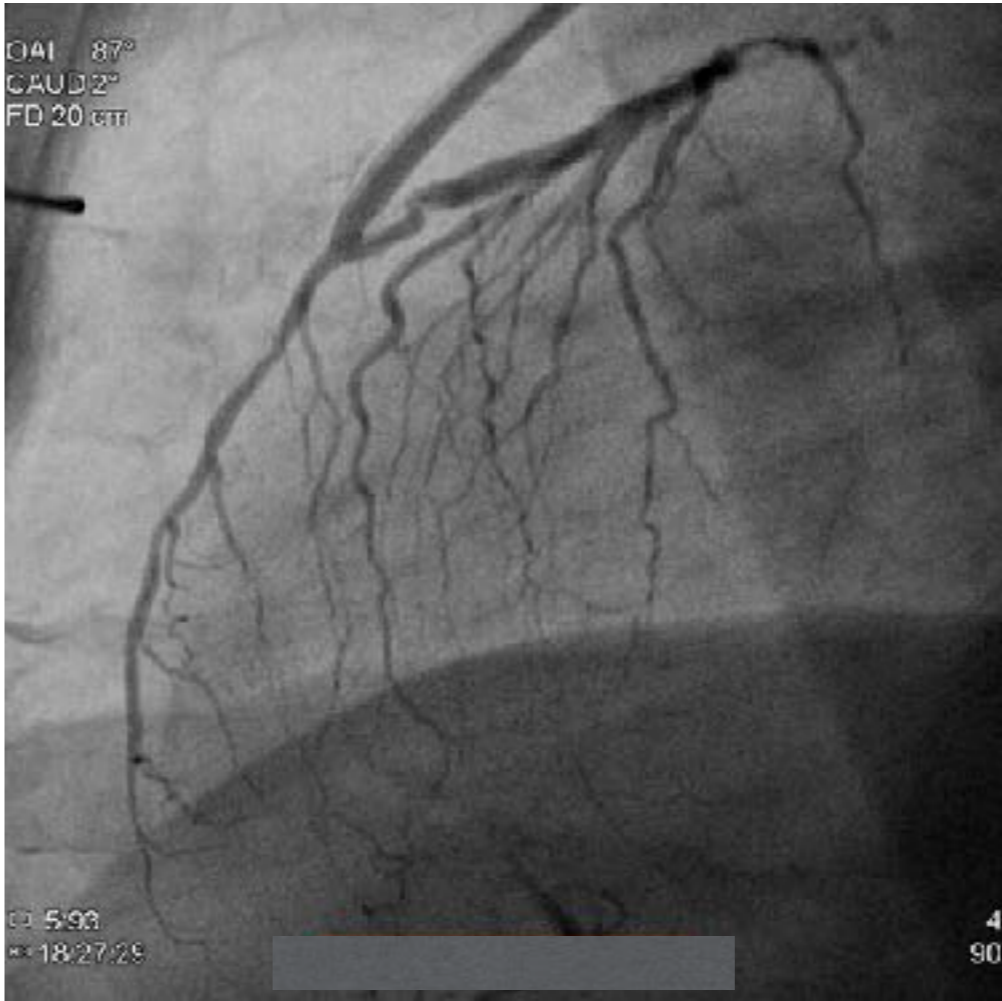
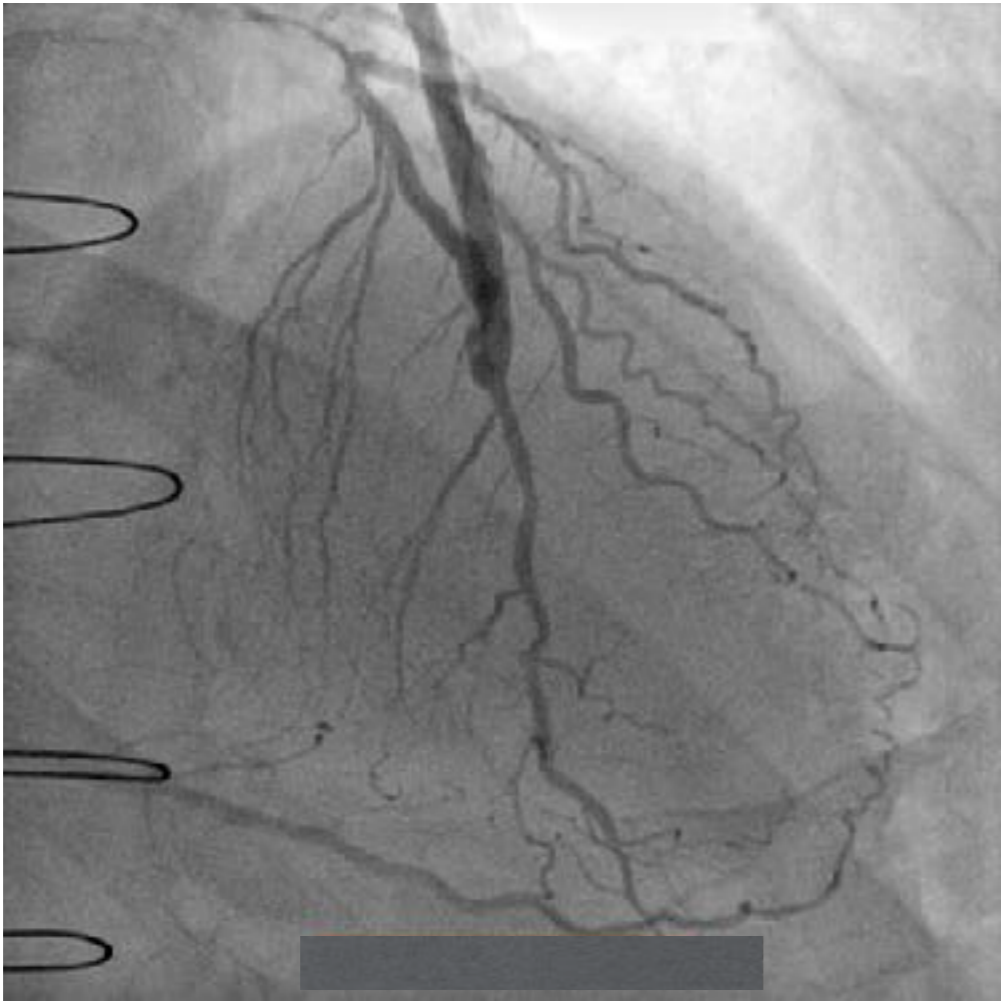


Coronariografía

Safena a CD ocluida, aspecto reciente, inyección con micro muy abundante trombo y oclusión distal.



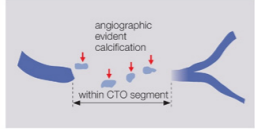
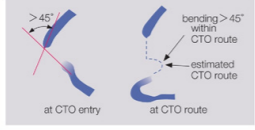
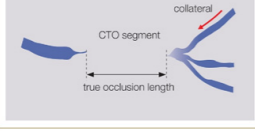


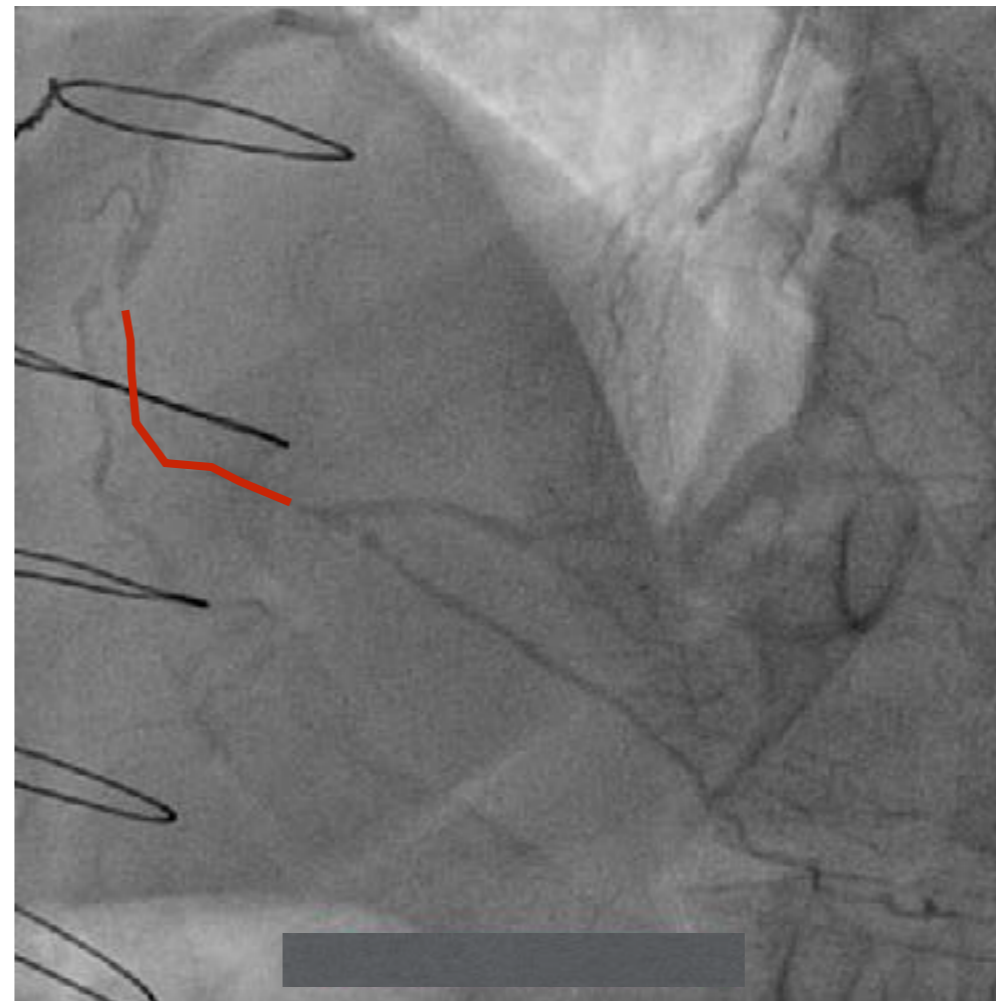
Coronariografia



Coronariografía

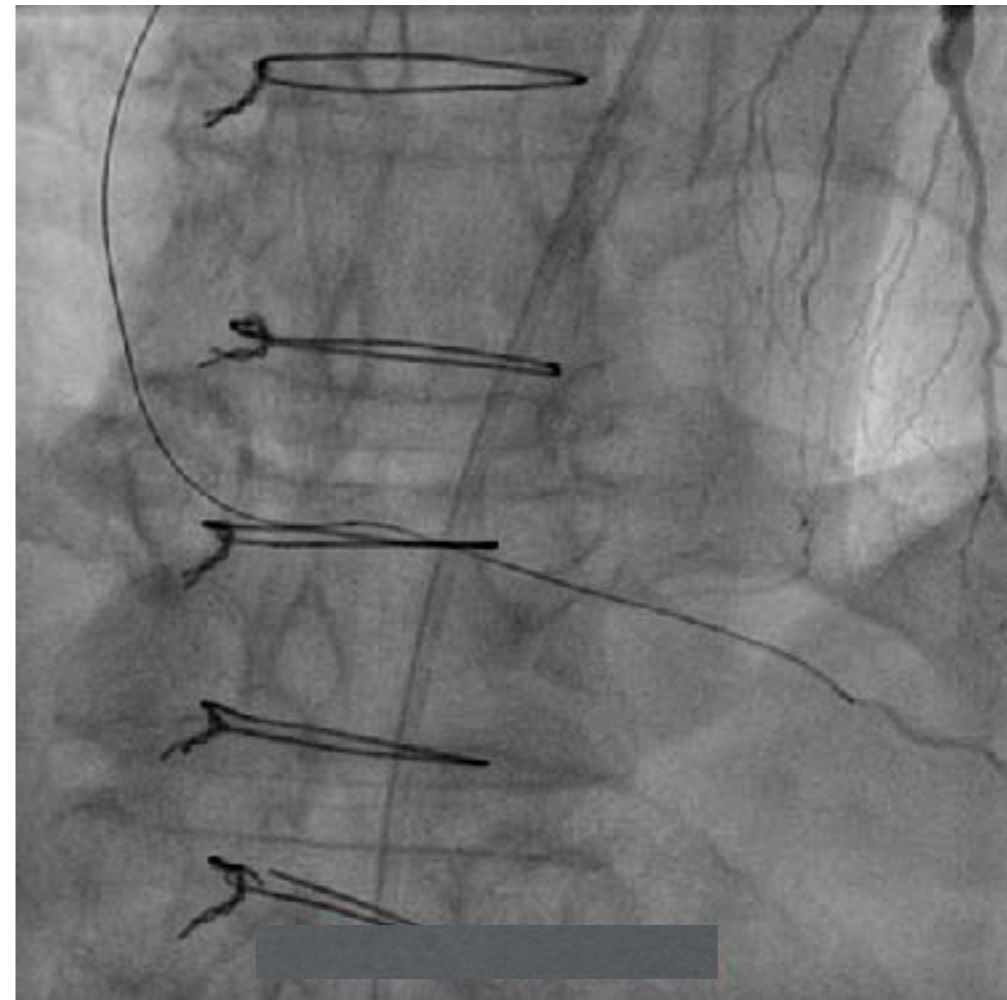
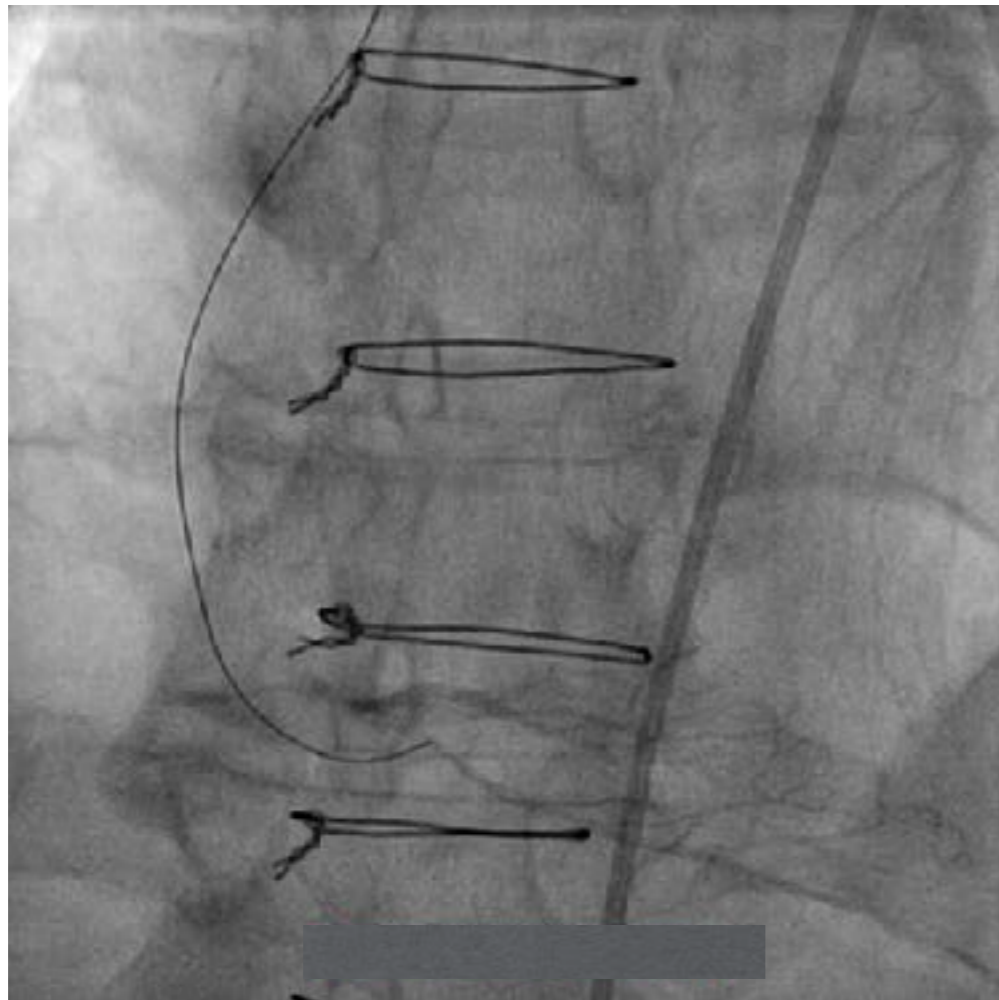
CTO de CD de alta dificultad

Variables and definitions		Version 1.0	
<p>Tapered</p> 	<p>Blunt</p> 	<p>Entry with any tapered tip or dimple indicating direction of true lumen is categorized as "tapered".</p>	<p>Entry shape</p> <input type="checkbox"/> Tapered (0) <input checked="" type="checkbox"/> Blunt (1)
<p>Calcification</p> 		<p>Regardless of severity, 1 point is assigned if any evident calcification is detected within the CTO segment.</p>	<p>Calcification</p> <input type="checkbox"/> Absence (0) <input checked="" type="checkbox"/> Presence (1)
<p>Bending >45degrees</p> 		<p>One point is assigned if bending > 45 degrees is detected within the CTO segment. Any tortuosity separated from the CTO segment is excluded from this assessment.</p>	<p>Bending >45°</p> <input type="checkbox"/> Absence (0) <input checked="" type="checkbox"/> Presence (1)
<p>Occlusion length</p> 		<p>Using good collateral images, try to measure "true" distance of occlusion, which tends to be shorter than the first impression.</p>	<p>Occl.Length</p> <input type="checkbox"/> <20mm (0) <input checked="" type="checkbox"/> ≥20mm (1)
<p>Re-try lesion</p> <p>Is this Re-try (2nd attempt) lesion ? (previously attempted but failed)</p>			<p>Re-try lesion</p> <input checked="" type="checkbox"/> No (0) <input type="checkbox"/> Yes (1)
<p>Category of difficulty (total point)</p> <input type="checkbox"/> easy (0) <input type="checkbox"/> Intermediate (1) <input type="checkbox"/> difficult (2) <input checked="" type="checkbox"/> very difficult (≥3)		<p>Total</p> <p>4 points</p>	

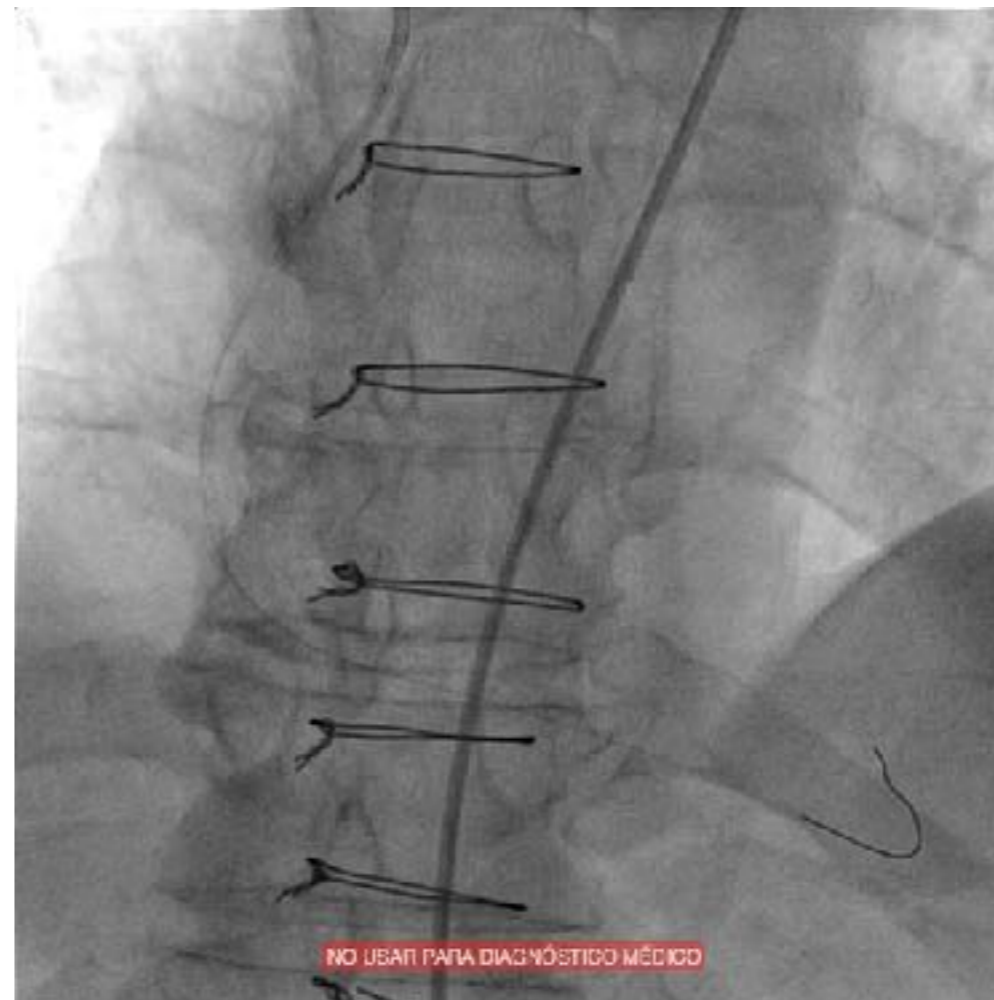
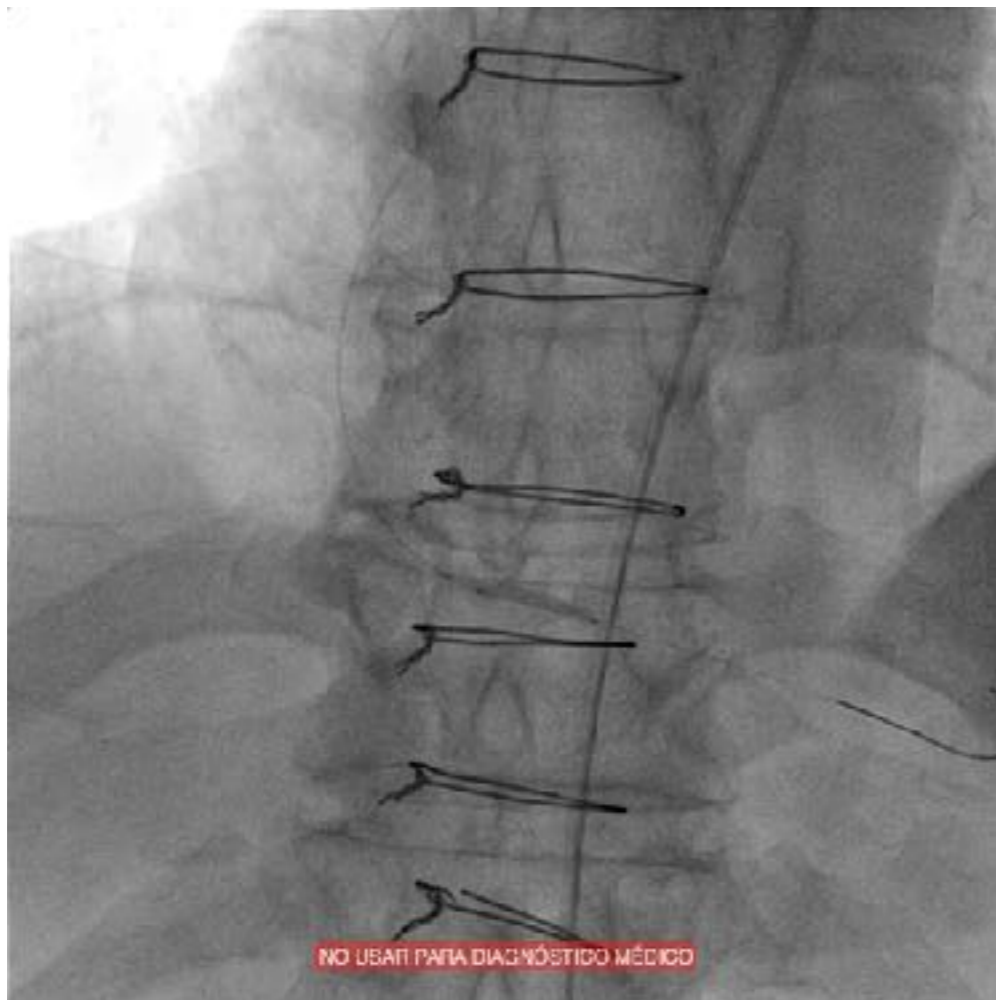


Se decide IPC de injerto de safena

Guia fielder XT y microcateter



Dilatación con balón diversos niveles



Aspiración de abundante trombo

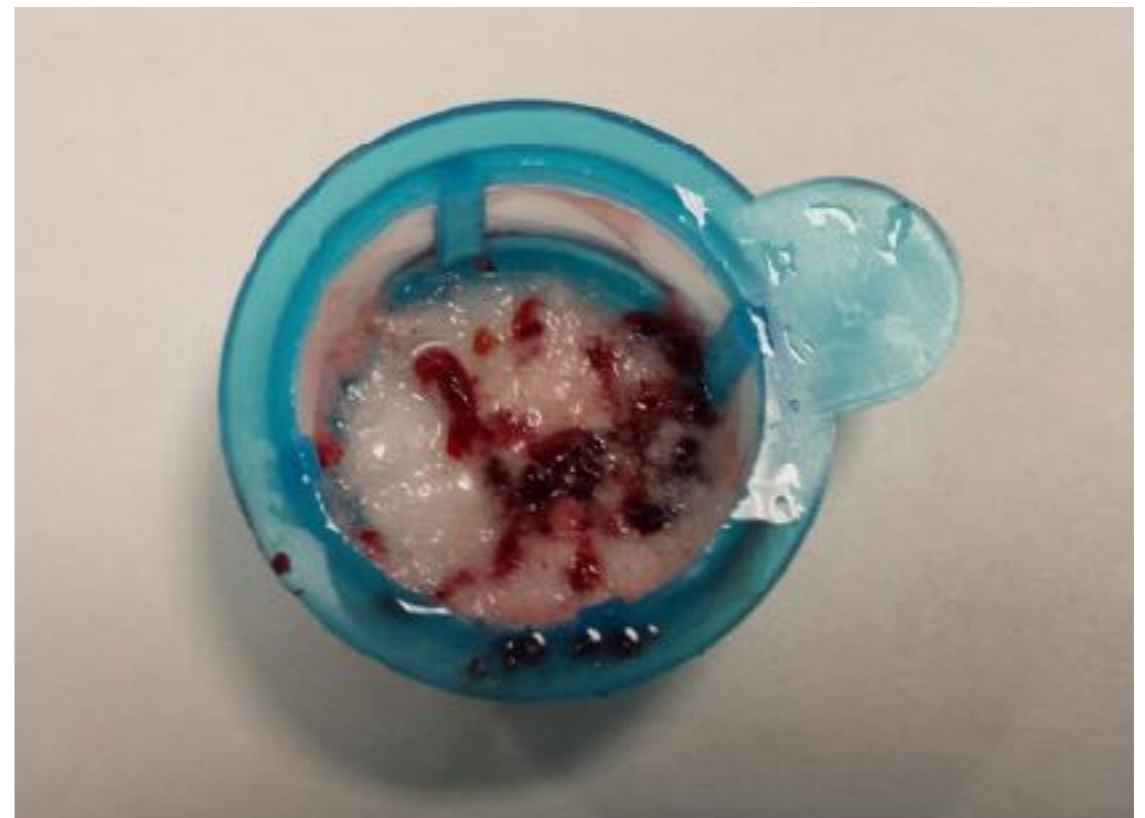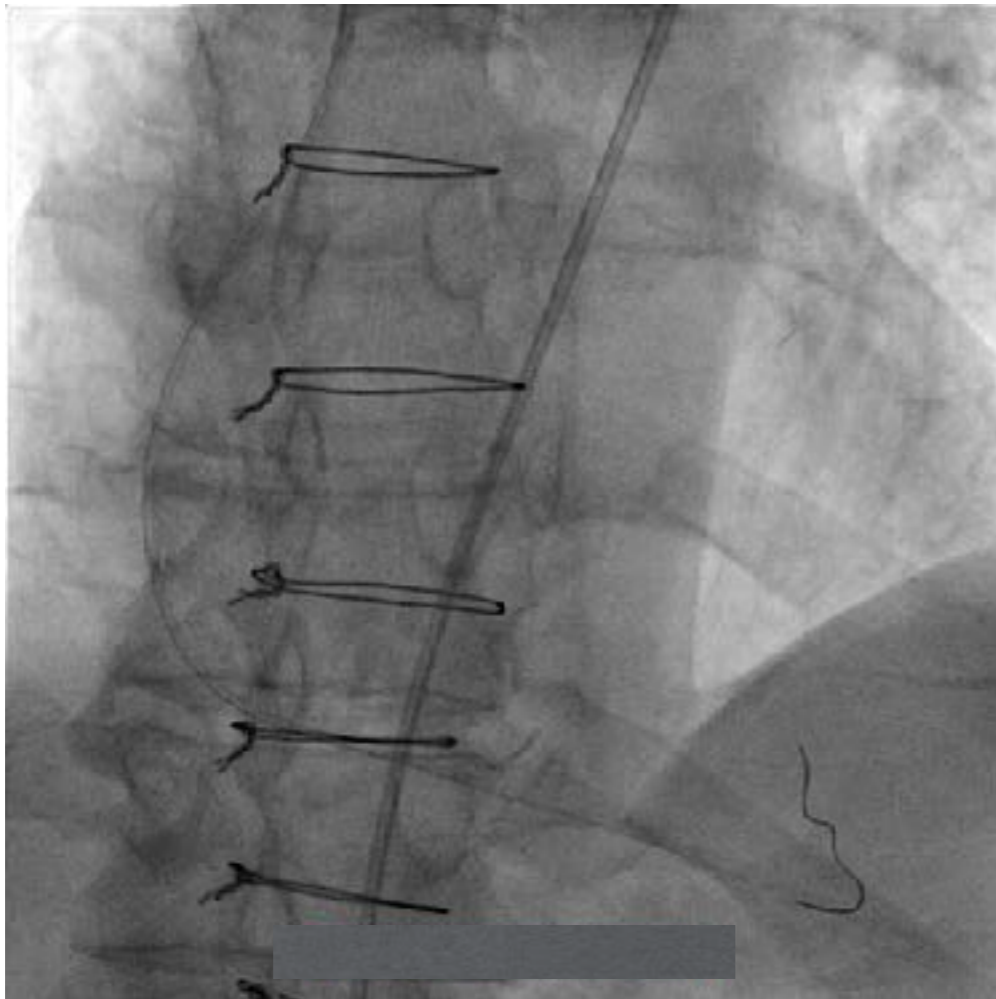
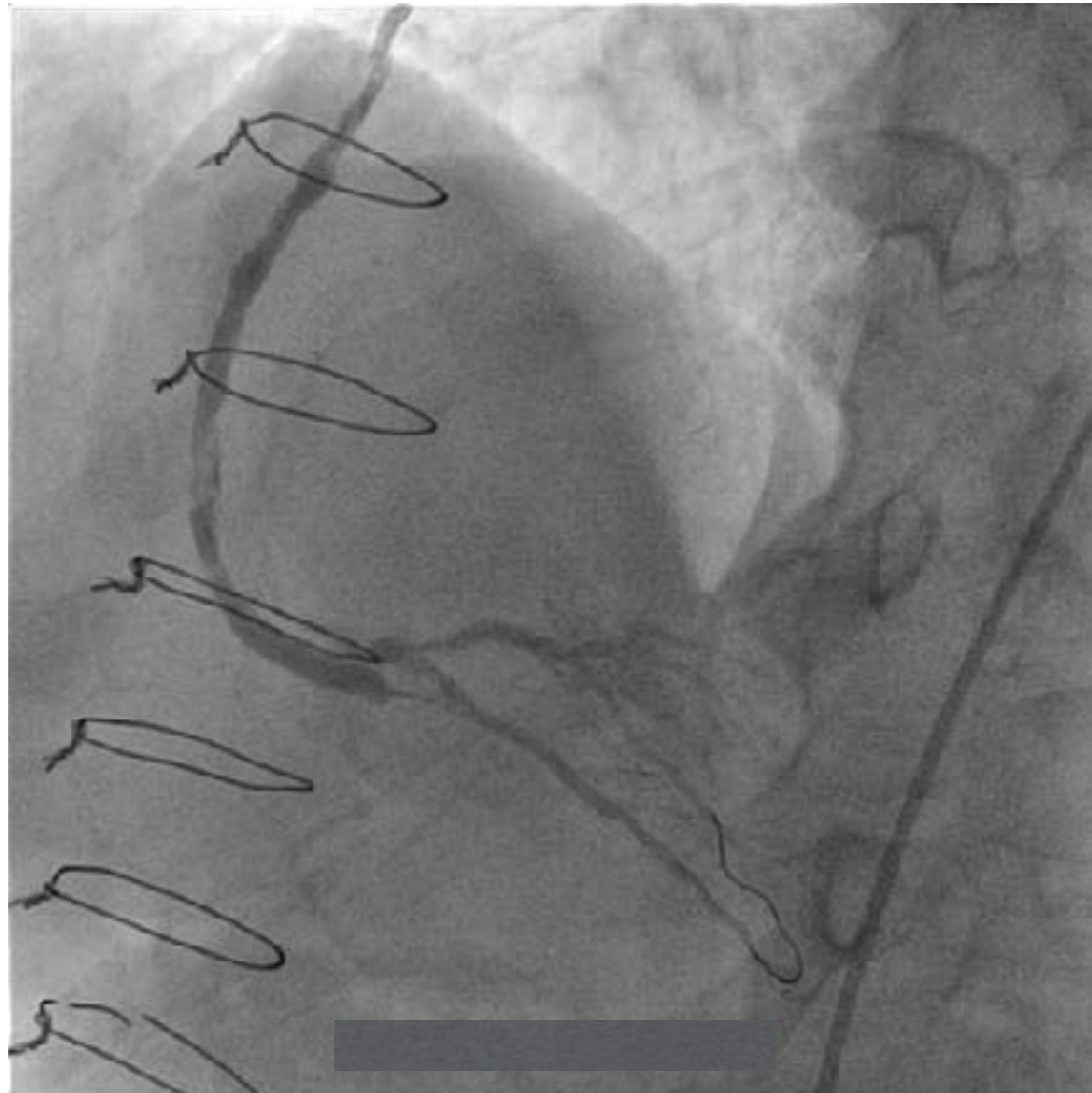
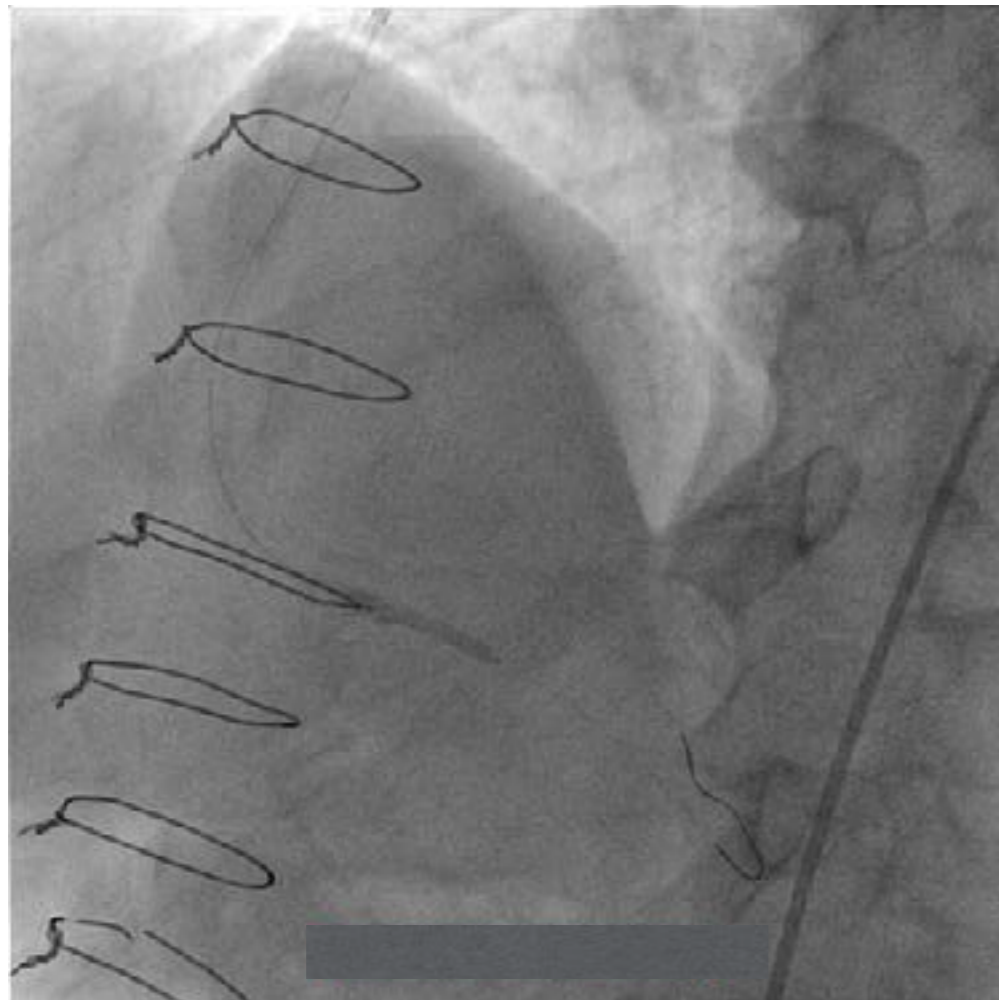


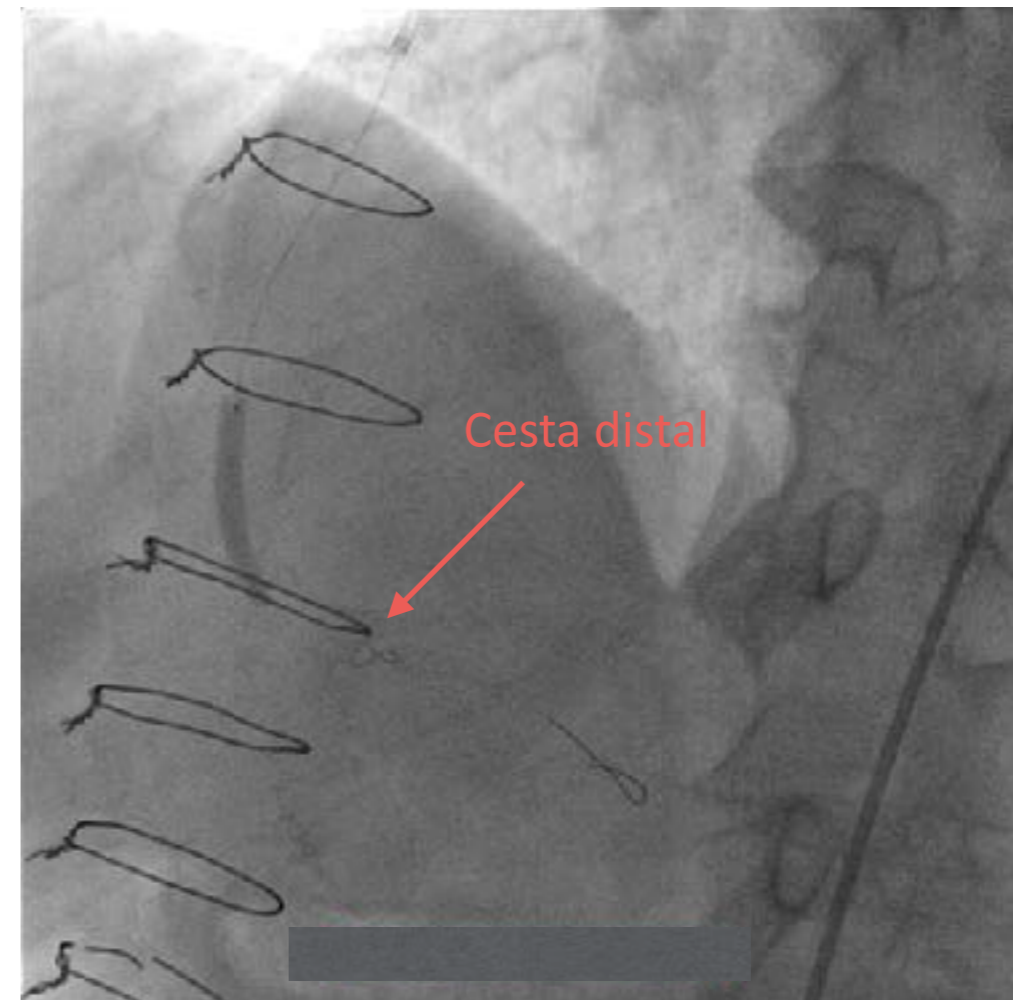
Imagen post aspiración



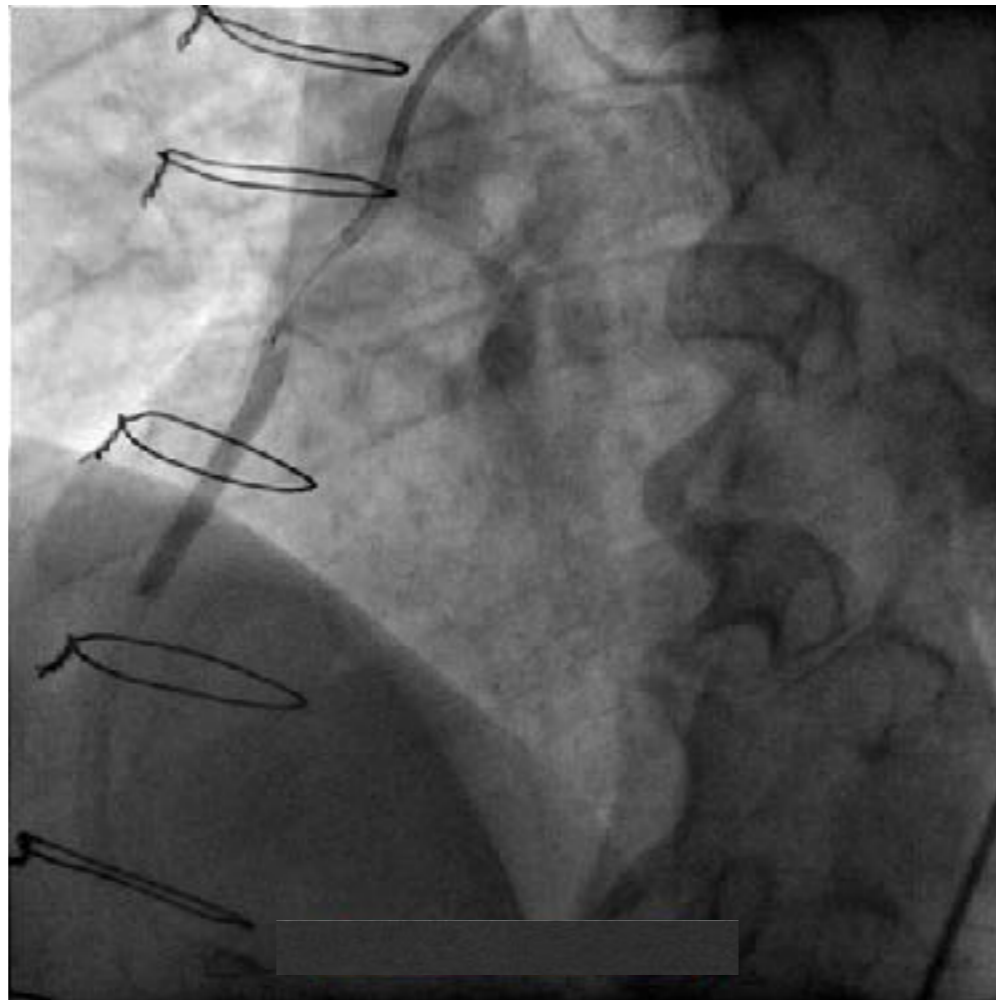
Stent anastomosis distal 2,5x14



Stent medio 3x18 con cesta distal



Stent proximal 3,5x28



Resultado final

